

9. Syrtsov V.K. Patterns of variability of lymphoid structures of the peripheral immune system / V.K. Syrtsov, V.M. Evtushenko, S.P. Kovalev, G.P. Koigushskaya // *Vyunik problems of medicine*. - 2003. - VIP. 3. - P. 8788.

10. Tshaev Sh.Zh., Khasanova D.A. Comparative characteristics of the morphological parameters of the lymphoid structures of the small intestine of rats before and after exposure to the antiseptic Dorogov stimulant fraction 2 against the background of chronic radiation sickness // *Operative surgery and clinical anatomy (Pirogov scientific journal)* 2019, Volume 3, No. 2, pp. 19-24.

11. Tshaev Sh.Zh., Khudoiberdiev D.K., Tshaeva D.Sh. Impact of exogenous and endogenous factors on the stomach wall // *Problems of biology and medicine*. 2018, No. 4(104). pp. 212-214.

12. Khudoiberdiev D.K., Tshaeva D.Sh. / Bir oilik ok kalamush oshkozon topography, oshkozon devorining macro microscope tuzilishi // *Biology va tibbiyot muammolari* 2020 No. 3 (119) - P. 165-168

УДК: 611.33:615.276:577.95.-092

CHANGES IN THE MORPHOMETRIC PARAMETERS OF THE GASTRIC WALL IN POLYPRAGMASS WITH ANTI-INFLAMMATORY DRUGS

Khudoyberdiev D.K. <https://ORCID:0009-0004-7508-7400>

Bukhara State Medical Institute

Summary. In recent years, as a result of various exposures to harmful factors has led to changes in the chemical and physical properties of the gastric mucosa and morphological instability of the composition of the gastric mucosa. Inflammation and destructive damage to the mucous membrane of the gastrointestinal tract, which occurs against the background of taking nonsteroidal anti-inflammatory drugs, occupies one of the leading positions in medical practice. The problem of treating these diseases is a clear example of the complexity of managing mainly comorbid conditions. The conclusion is that when more than three types of anti-inflammatory drugs are used, as a result of their action, the size of the mucous layer of the gastric wall, the base of the mucous membrane is significantly reduced.

Key words: stomach, stomach wall, mucous membrane, polypharmacy, lymph, tissue

ИЗМЕНЕНИЯ МОРФОМЕТРИЧЕСКИХ ПАРАМЕТРОВ СТЕНКИ ЖЕЛУДКА ПРИ ПОЛИПРАГМАЗИИ ПРОТИВОВОСПАЛИТЕЛЬНЫМИ ПРЕПАРАТАМИ

Худойбердиев Д.К. <https://ORCID:0009-0004-7508-7400>

Бухарский государственный медицинский институт

Резюме.

В последние годы различные воздействия вредных факторов приводят к изменению химических, физических свойств слизистой оболочки желудка и морфологической нестабильности состава слизистой оболочки желудка. Воспалительные и деструктивные поражения слизистой желудочно-кишечного тракта, возникающие на фоне приема нестероидных противовоспалительных препаратов, занимают в врачебной практике одно из ведущих мест. Проблема лечения этих заболеваний является ярким примером сложности управления преимущественно сопутствующими заболеваниями. Вывод заключается в том, что при применении более трех видов противовоспалительных препаратов в результате их действия значительно уменьшаются размеры слизистой оболочки стенки желудка, основания слизи.

Ключевые слова: желудок, стенка желудка, слизистая оболочка, полипрагмазия, лимфа, ткань

ЯЛЛИҒЛАНИШГА ҚАРШИ ДОРИ ВОСИТАЛАРИ БИЛАН ПОЛИПРАГМАЗИЯДА ОШҚОЗОН ДЕВОРИНИНГ МОРФОМЕТРИК ПАРАМЕТРЛАРИДАГИ ЎЗГАРИШЛАРИ

Xudoyberdiev D. K. <https://ORCID:0009-0004-7508-7400>

Buxoro davlat tibbiyot instituti

Xulosa.

Сўнги йилларда зарарли омилларнинг турли хил таъсири натижасида меъда шиллиқ қаватининг кимёвий, физик хусусиятларининг ўзгаришига ва меъда шиллиқ қавати таркибининг морфологик беқарорлигига олиб келмоқди. Ностероид яллиғланишга қарши дорилар қабул қилиш фониди юзага келадиган ошқозон-ичак

тракти шиллиқ қаватининг яллиғланиши ва деструктив зарарланиши, шифокор амалиётида етакчи ўринлардан бирини эгаллайди. Бу касалликларни даволаш муаммоси асосан коморбид шароитларни бошқаришнинг мураккаблигига яққол мисол бўла олади. Хулоса шундан иборатки, яллиғланишга қарши дориларнинг учдан ортиқ тури қўлланилганда, уларнинг таъсири оқибатида меъда деворининг шиллиқ қавати, шиллиқости асоси ўлчамлари сезиларли даражада пасайди.

Калит сўзлар: меъда, меъда девори, шиллиқ қават, полипрагмазия, лимфа, тўқима

Introduction Studies in recent years have shown that 35% of the population suffers from gastritis and peptic ulcer disease. The study of organ-induced changes in the factors affecting the morphology of the gastric mucosa has been accelerating in recent years [20].

According to the scientific literature, the organs of the digestive system are inextricably linked with the external environment. Therefore, the mucous membrane of the organs of the digestive tract is affected by food. These effects occur in constant contact with the lymphoid tissue of the gastric mucosa and the subcutaneous base, which is the immune system [11, 12]. Long-term dry and solid nutrition has been shown to cause stable deviations in the morphogenetic structure of the gastric mucosa [13,19].

In recent years, as a result of various exposures to harmful factors has led to changes in the chemical and physical properties of the gastric mucosa and morphological instability of the composition of the gastric mucosa [10,23]. Inflammation and destructive damage to the mucous membrane of the gastrointestinal tract, which occurs against the background of taking nonsteroidal anti-inflammatory drugs, occupies one of the leading positions in medical practice. The problem of treating these diseases is a clear example of the complexity of managing mainly comorbid conditions. If we refer to the results of any clinical trials, the presence of comorbidity is often the exception criterion [14,21].

Some sources provide an acceptable definition of polypragmasia - the prescribing of more drugs (5 or more) than the clinical condition and quantitative determination - which is called polypragmass. In medical dictionaries, polypragmaa is also referred to as a "single prescription" kit. Most often, this phenomenon is observed in elderly patients [8,9].

Side effects of these groups of drugs are naturally associated primarily with damage to the mucous membrane of the gastrointestinal tract and the urinary system [2,3]. Thus, damage to the gastric mucosa resulting from long-term use of nonsteroidal anti-inflammatory drugs also leads to the development of life-threatening conditions and a decrease in adaptive response [15,16,17].

The data presented show that currently the fight against polypragmass with anti-inflammatory drugs is one of the important tasks of medical care for patients of any age. This highlights the need to develop a strategy for the effective and safe use of drugs in the treatment of patients that improves the quality of care and reduces unwanted drug reactions [19,20].

The gastrointestinal tract is the most complex system of interpretation and interaction of the digestive organs. They are all inextricably linked. Disruption of a single body can lead to failure of the entire system. They all perform their functions and ensure the normal functioning of the body. All parts of the fracture are interrelated and pathological processes affect one of the sections [1,4,7].

However, due to the dynamics of structural changes of the gastric mucosa, the specific features of certain etiological factors can be considered as a typical pathological process (chronic inflammation) in a number of professions [5,6]. From the above, it is clear that the work done on studies of polypragmass and its effects on the gastrointestinal tract is insufficient. There are some inconsistencies between the available data, which require further morphological and morphometric investigations.

Materials and methods: The experiment was performed in vivarium conditions in a total of 114 white non-breeding rats. Attention was paid to these storage conditions of rats at room temperature, in natural light and in ventilated, separate cages. In the early stages of the scientific experiments, all sexually mature rats were quarantined for seven days and transferred to the normal vivariate regimen after denial of somatic or infectious diseases. During the experiment, the physiological condition and behavior of the rats in the control group and the comparison group were carefully monitored.

The following anti-inflammatory drugs were used to study the effect of polyfragmas in experimental groups of animals: Aspirin (NYaQD - salicylic acid derivatives), Paracetamol (NYaQD - anilide derivatives),

Ibuprofen (NYaQD - propionic acid derivatives), Dexamethasone (synthetic anti-inflammatory) effective anti-malarial agent).

Results: No significant change in body weight was observed in experimental rats compared with control group I, ie control animals, during the 150-day period of administration of nonspecific anti-inflammatory drugs (NAS) in different variants. Group III decreased by 3.8%, group IV by 6.1%, and our group V by 8.5% (Figure 1). The experiments revealed the homogeneity of the gastric mucosa layer, mucosal base and large and small curves of the stomach, and the best informative indicators were the total thickness of the gastric wall, mucosal layer thickness, mucosal base thickness, folds height, glandular tissue height, pit height between folds. The accuracy of the results and the degree of their recovery were found to depend on the intake of nonsteroidal anti-inflammatory drugs by laboratory animals.

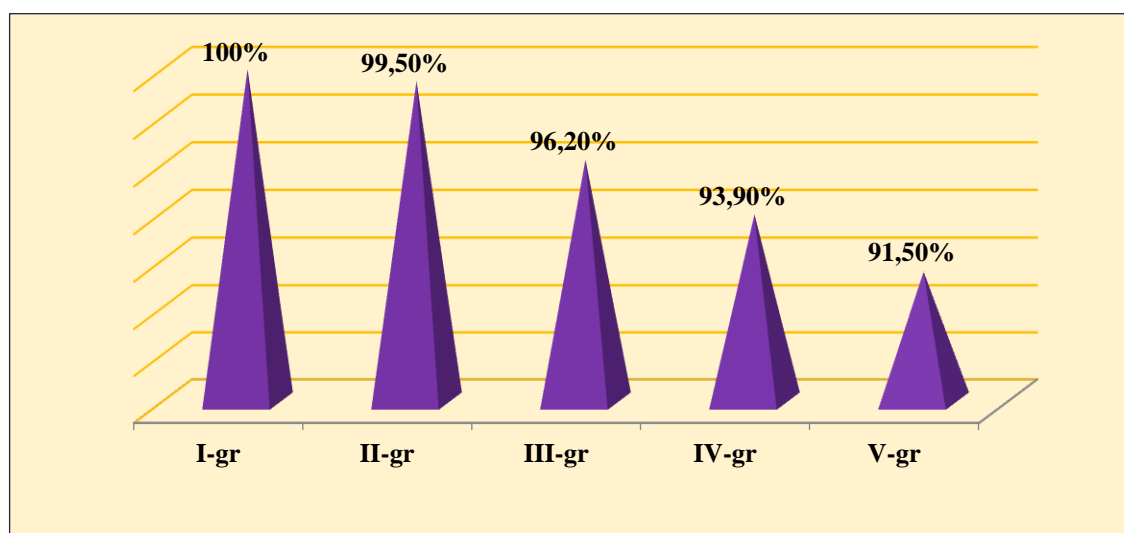


Figure 1. Changes in body weight (%) of white non-white rats over a period of 5 months under the influence of polypragmass.

The morphometric parameters of the gastric wall of 5-month-old white rats in the experiment were as follows: the total thickness of the gastric wall increased from -671.8 microns to -814.5 microns in the cardiac part, on average - 738.6 ± 15.41 microns; from -786.9 microns in the pyloric part -973 , Up to 1 µm, averaging -832.4 ± 20.11 µm. The thickness of the mucous layer in the cardiac part ranged from -434.3 µm to -512.1 µm, with an average of -458.4 ± 8.40 µm; in the pyloric region -373.4 µm to -489.2 µm, with an average of -443.4 ± 12.51 µm. The thickness of the submucosal base ranged from -39.6 µm to -45.79 µm in the cardiac region, averaging -41.3 ±

0.66 μm ; in the pyloric region from -39.1 microns to -51.9 microns, with an average of -46.8 ± 1.38 microns.

Table 1

Components of the stomach wall	Cardiac section (mkm)	depth (mkm)	body (mkm)	Pyloric section (mkm)
The total thickness of the stomach wall	671,8-814,5 738,6 \pm 15,41	622,3-796,5 706,1 \pm 11,18	714,5-803,7 768,6 \pm 16,12	786,9-973,1 832,4 \pm 20,11
The thickness of the mucous membrane	434,3-512,1 458,4 \pm 8,40	414,9-500,9 441,4 \pm 7,15	401,3-498,1 446,4 \pm 9,30	373,4-489,2 443,4 \pm 12,51
The height of the fold	426,5-503,1 441,3 \pm 8,27	436,5-513,1 459,3 \pm 5,27	446,5-529,1 486,3 \pm 5,97	364,5-461,6 410,1 \pm 10,49
Cloth tissue	19,2-27,4 23,4 \pm 0,89	17,2-27,4 21,4 \pm 0,28	18,2-31,4 24,4 \pm 0,75	18,9-24,1 20,3 \pm 0,56
The base of the mucous membrane	39,6-45,7 41,3 \pm 0,66	38,9-42,7 40,1 \pm 0,62	39,8-47,7 43,1 \pm 0,86	39,1-51,9 46,8 \pm 1,38

The height of the glandular tissue located in the mucous layer ranged from -19.2 μm to -27.4 μm in the cardiac region, averaging -23.4 ± 0.89 μm ; in the pyloric region -18.9 μm to -24.1 μm , with an average of -20.3 ± 0.56 μm . When rats reach 5 months of age, the cardiac compartment contains glands containing $19.2 * 0.4$ head cells. In this case, the number of stem cells in the glands of the pyloric duct is $-21.4 * 0.7$, parietal cells - $15.1 * 0.6$ (Figure 2). Parietal gland cells in the neck and neck area are characterized by the presence of $-21.1 * 0.5$ in the cardiac part, pyloric duct glandular cells $-16.7 * 0.5$, mucus-producing glandular cells $-14.7 * 0.6$.

The thickness of the organ ranged from -12 mm to -13 mm and averaged -12.43 ± 0.22 mm. The length of the large curve ranged from -36 mm to -37 mm, with an average of -36.36 ± 0.11 mm. The length of the small curve ranged from -13 mm to -14 mm, with an average of -13.45 ± 0.11 mm. During this period, the total thickness of the gastric wall in the cardiac part of laboratory rats increased from -664.2 μm to -758.1 μm , on average -719.8 ± 10.14 μm , and in the pyloric part - from -728.4 μm to -856.3 μm , on average -786.3 ± 13.81 microns.

Table 2

Components of the stomach wall	Cardiac section (mkm)	depth (mkm)	body (mkm)	Pyloric section (mkm)
The total thickness of the stomach wall	648,5-814,3 739,8±17,91	667,5-845,3 779,2±14,61	688,3-857,5 786,4±11,01	775,8-986,4 853,7±22,74
The thickness of the mucous membrane	426,9-532,5 478,7±11,40	436,9-582,5 498,7±12,41	421,9-554,5 495,7±15,07	365,2-498,5 439,1±14,40
The height of the fold	406,5-501,3 438,9±10,23	396,5-485,2 441,9±9,28	401,5-515,4 447,9±12,21	373,6-451,9 421,6±8,46
Cloth tissue	19,0-26,3 23,8±0,79	18,0-27,3 21,9±0,34	19,8-24,3 22,1±0,52	18,3-25,4 21,6±0,77
The base of the mucous membrane	32,3-40,9 35,8±0,93	31,1-39,9 34,8±0,53	32,9-42,2 37,7±0,82	38,8-53,7 46,8±1,61

Morphological and morphometric studies confirmed the visually determined patterns: the total wall thickness, fold height, mucosal layer, mucosal base, and glandular tissue height measurements in the 5-month experimental animals were 12.72%, 8.15%, and 18, respectively. , 37%, e, group 4 experimental rats decreased by 4.62%, 4.55% and 10.19%, group 3 animals decreased by 3.91%, 2.21% and 4.17% of the experiment, 2 In experimental rats, it was noted that the 1st group of the experiment was the same size as the experimental animals.

Conclusion.

Thus, the results obtained showed that when we inject different amounts of drugs into the body, there are different levels of morphological and morphometric changes in their effects on tissues and cells. The effects of anti-inflammatory drugs on gastric wall elements in white non-white rats have been studied experimentally. When more than three types of anti-inflammatory drugs were used, it was found that their effect was significantly reduced in the size of the mucous layer of the gastric wall, the base of the mucosa.

REFERENCE:

1. Алисейко Е. А., Громов И. Н. Влияние лития карбоната на морфологию лимфоидного аппарата органов пищеварения цыплят, вакцинированных против инфекционной бурсальной болезни // Актуальные проблемы интенсивного развития животноводства. - 2011. - №14 (2). - С. 101-107.
2. Аминова Г. Г., Григоренко Д. Е. Слизистая оболочка полых внутренних органов и ее роль в иммунных процессах // Актуальные проблемы гуманитарных и естественных наук. - 2012. - №8.
3. Беляева Е.В., Гуцин Я.А. Методы визуализации и исследования кишечечно-ассоциированной лимфоидной ткани лабораторных животных // Лабораторные животные для научных исследований. - 2020. - №3. - С. 68-74.
4. Востроилова Г.А., Паршин П.А., Михайлов Е.В., Толкачев И.С., Хохлова Н.А., Чаплыгина Ю.А. Гисто-морфометрические показатели слизистой оболочки тонкого кишечника у поросят-гипотрофиков при применении Биферона-С и Аминоселеферона // Ветеринарный фармакологический вестник. - 2019. - № 2 (7). - С. 21-28.
5. Гладких Ф.В. Превентивно-лечебные стратегии фармакокоррекции гастропатии, индуцированной нестероидными противовоспалительными препаратами // Обзоры по клинической фармакологии и лекарственной терапии.-2017.-Т.15.-№4.-С.14-23.
6. Григоренко Д.Е., Васянина К.А. Лимфоидные структуры в стенке двенадцатиперстной кишки и в пейеровой бляшке подвздошной кишки крыс при моделировании гипокинезии//Клиническая и экспериментальная морфология. - 2013. - № 3 (15). - С. 47-51.
7. Гринь В.Г. Ангио архитектоника пейеровых бляшек тонкой кишки белых крыс // Журнал ГрГМУ.- 2019.- №6. -С. 662-664.
8. Гусейнов Т.С, Гусейнова С.Т., Халилов М.А. Некоторые особенности макро и микроскопической анатомии структур стенки желудка крыс при воздействии сероводородных ванн // Вестник новых медицинских технологий. Электронное издание. - 2020. - №5. - С. 125-129.
9. Гусейнов Т.С., Гусейнова С.Т., Гасанова М.А., Кудаева П.Д. Морфология кишечечно-ассоциированной лимфоидной ткани при бальнеопроцедурах // Известия вузов. Поволжский регион. Медицинские науки. 2017. - №3 (43). - С. 13-22.

10. Каратеев А.Е., Насонов Е.Л., Яхно Н.Н., Ивашкин В.Т., Чичасова Н.В., Алексеева Л.И. и другие. Рациональное применение нестероидных противовоспалительных препаратов (НПВП) в клинической практике // Клинические рекомендации. Современная ревматология. №1. 2015. С.4-18.

11. Пожариская Т.Д., Смирнова О.Ю., Бобков П.С., Денисова Г.Н. Участие циркулирующих лимфоцитов в постлучевом восстановлении клеточного состава лимфатических узлов // Морфология. 2016. Т. 149, № 3. - С. 163 - 164.

12. Прошина Л.Г., Семенов К.В. Структурные функционально-метаболические изменения клеток системы мононуклеарных фагоцитов и лимфоцитов при экспериментальных воздействиях // Морфологические ведомости, - 2004, №1-2, - С. 84 – 88.

13. Санжапова, А.Ф. О развитии структур стенки фундального отдела желудка белых крыс при питании диспергированной пищей // Сборник материалов I конференции молодых ученых медико-биологической секции Поволжской ассоциации государственных университетов. - Ульяновск, - 2007. - С. 62 - 63.

14. Софронов В.Г., Аухадиева З.Ф., Медетханов Ф.А. Изучение противовоспалительных свойств комплексного средства з-88 // Сборник научных трудов СКНИИЖ. - 2021. - №1. - С. 109-112.

15. Тарасова Л. В., Трухан Д. И. Лекарственная безопасность в гастроэнтерологии // Экспериментальная и клиническая гастроэнтерология. - 2013. - №4. - С.81-86.

16. Трухан Д.И., Тарасова Л.В. Лекарственная безопасность и рациональная фармакотерапия в гастроэнтерологической практике // Клинические перспективы гастроэнтерологии, гепатологии.- 2013.- № 5.- С. 3-10.

17. Трухан Д.Н. Нестероидные противовоспалительные препараты сквозь призму коморбидности и лекарственной безопасности: в фокусе - амтолметин гуацил // Consilium Medicum. - 2015. - №2. - С.27-33.

18. Худойбердиев Д.К. Влияние факторов внешней среды на морфологию желудка // Биология ва тиббиёт муаммолари. Самарқанд, -2019. - №3 (111). – С.295-297.

19. Худойбердиев Д.К., Наврузов Р.Р., Тешаева Д.Ш. Оқ каламуш ошқозони морфометрик параметрларининг илк постнатал

даврдаги ўзига хос хусусиятлари // Биология ва тиббиёт муаммолари.– Самарқанд, 2020. - №5 (122). – С.231-234.

20. Худойбердиев Д.К., Тешаева Д.Ш. / Бир ойлик оқ каламуш ошқозони топографияси, ошқозон деворининг макро- ва микроскопик тузилиши // Биология ва тиббиёт муаммолари 2020 й №3 (119) - С.165-168.

УДК:611.591.523/636.92.616.24-002

СОВРЕМЕННАЯ ДИАГНОСТИКА ПОВРЕЖДЕНИЙ МЕНИСКОВ ПРИ ТРАВМЕ КОЛЕННОГО СУСТАВА

Худойбердиев Д. К. <https://ORCID:0009-0004-7508-7400>

Остонова М.Н.

Бухарский государственный медицинский институт

Аннотация. Внедрение в клиническую практику современных высокоинформативных инструментальных методов существенно расширило возможности ранней диагностики повреждений коленного сустава. В настоящее время предпочтение отдается методам исследования, которые, помимо высокой информативности обладают такими качествами, как неинвазивность, безвредность, характеризуются простотой выполнения и трактовки результатов, воспроизводимостью и низкой стоимостью исследования.

Ключевые слова: ультразвуковое исследование, магнитно-резонансная томография, мениск, коленный сустав.

MODERN DIAGNOSTICS OF MENISCUS INJURIES IN KNEE JOINT INJURY

Khudaiberdyev D. K. <https://ORCID:0009-0004-7508-7400>

Ostonova M.N.

Bukhara State Medical Institute

Resume: The introduction of modern highly informative instrumental methods into clinical practice has significantly expanded the possibilities of early diagnosis of knee joint injuries. Currently, preference is given to research methods that, in addition to being highly informative, have such qualities as non-invasiveness, harmlessness, are characterized by