

3. Волков М.В., Самойлович Э.Ф., Серафин Ю.Я. Врожденные и приобретенные изменения менисков коленного сустава у детей // Хирургия.-2004.- №8.-С.38-45.

4. Rodeo S. Meniscal allografts Where do we stand? // Am. J. Sports Med.-2008.- Vol. 29. -P. 246-261.

5. The long-term functional outcome of operatively treated tibial plateau fractures / Stevens D.G., Beharry R., McKee M.D. et al. // J. Orthop. Trauma. 2003.- Vol. 15,N5. - P.312-20.

6. Худойбердиев Д., Хасанов О. Методы лучевой диагностики в оценке изменений тазобедренного сустава //Журнал проблемы биологии и медицины. – 2016. – №. 4 (91). – С. 193-196.

7. Худойбердиев Дилшод Каримович, Джураев Нодир Аблокулович, Лучевая диагностика патологий молочной железы у женщин с гипотиреозом//Journal of Advanced Research and Stability Volume: 03 Issue: 04 | Apr - 2023 ISSN: 2181-2608 247-254

8. Khudoyberdiev Dilshod Karimovich, Ostonova Malohat Namoz qizi. MRI diagnostics of meniski injuries in knee joint injury//International multidisciplinary journalof development of the scientific world (IMJDSW)/Volume 1 Issue, 3 September 2022, P-25-31

9. Худойбердиев Д.К. Влияние факторов внешней среды на морфологию желудка // Биология ва тиббиёт муаммолари. Самарқанд,-2019. - №3 (111). – С.295-297. (14.00.00; № 19)

10. Xudoyberdiyev D. K. et al. Morphological Characteristics Of Morphometric Parameters Of The Gastric Mucosa In Polypragmasia With Anti-Inflammatory Drugs //Eurasian Scientific Herald. – 2022. – Т. 4. – С. 1-7.

УДК: 611-018.61:616.831.001(756):616-092.2

MORPHOLOGICAL CHARACTERISTICS OF THE KIDNEYS ON THE 3TH, 14TH 21TH DAYS DURING THE PROLONGED PERIOD OF MODERATE BRAIN INJURY.

Khuseynova Gulshan Khuseynovna. <https://orcid.org/my-orcid?orcid=0000-0001-8773-9999>

*Bukhara State Medical Institute, Department of Anatomy,
Clinical Anatomy (OSTA).*

Summary: *This article presents information about the results of scientific studies that allow to evaluate and study the morphological features of the kidneys*

of 3-month-old rats after moderately severe brain injuries. Morphological analysis of rat kidneys was performed on days 3, 14, 21 after brain injury.

Keywords: traumatic brain injury, kidneys, nephron, biopsy, Shumlyansky-Bowman's capsule, vascular glomerulus.

ЎРТАЧА ОҒИР ДАРАЖАДА БОШ МИЯ ШИКАСТЛАНИШИНИНГ УЗОҚЛАШИРИЛГАН ДАВРИДА 3-, 14-, 21- КУНИ БУЙРАКЛАРНИНГ МОРФОЛОГИК ХУСУСИЯТЛАРИ.

Хусейнова Гулшан Хусейновна. <https://orcid.org/my-orcid?orcid=0000-0001-8773-9999>

Бухоро давлат тиббиёт институти анатомия, клиник анатомия
(ОХТА) кафедраси

Аннотация: Ушбу мақолада ўртача оғир даражадаги бош мианинг шикастланиши оқибатида 3 ойлик каламушлар буйракларининг морфологик хусусиятларини баҳолаш ва ўрганиш мумкин бўлган илмий тадқиқотлар натижалари ҳақида маълумотлар келтирилган. Каламуш буйракларини морфологик таҳлили бош миЯ шикастланишдан кейинги 3-, 14-, 21- кунларда ўтказилган.

Калит сўзлар: бош миЯ шикастланиши, буйраклар, нефрон, биоптат, Шумлянский-Боумен капсуласи, томирли коптокча.

МОРФОЛОГИЧЕСКАЯ ХАРАКТЕРИСТИКА ПОЧЕК НА 3-Й, 14- Й, 21-Й ДНИ В ТЕЧЕНИЕ ОТДАЛЁННОГО ПЕРИОДА СРЕДНЕМЕРНОЙ ЧЕРЕПНО-МОЗГОВОЙ ТРАВМЫ.

Хусейнова Гулшан Хусейновна.
<https://orcid.org/my-orcid?orcid=0000-0001-8773-9999>

Бухарский государственный медицинский институт, кафедра анатомии,
клинической анатомии (ОХТА).

Резюме: В данной статье представлены сведения о результатах научных исследований, позволяющих оценить и изучить морфологические особенности почек 3-месячных крыс после средне - тяжелых травм головного мозга. Морфологический анализ почек крыс проводили на 3-е, 14-е, 21-и сутки после травмы головного мозга.

Ключевые слова: черепно-мозговая травма, почки, нефрон, биопсия, капсула Шумлянского-Боумена, сосудистый клубочек.

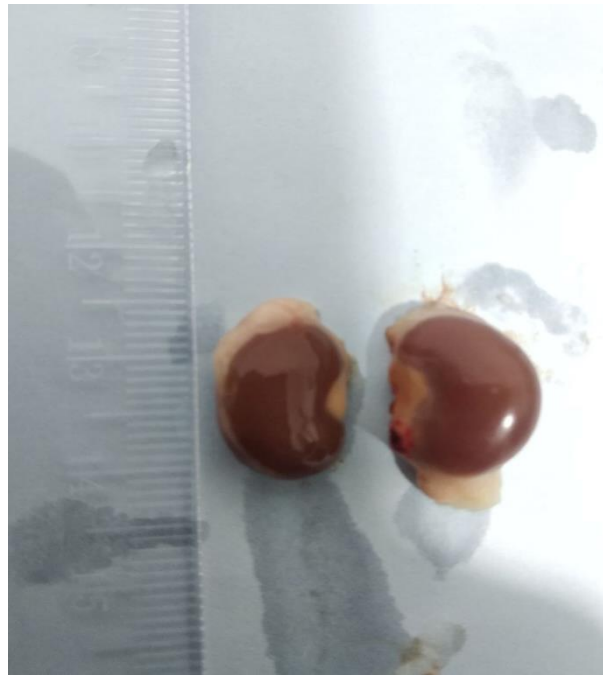Abstract: In our country, many targeted measures are being implemented to fundamentally improve the healthcare system and improve the quality of prompt and qualified medical care provided to the population [6,7,10,12,21,25,35,36,42]. At the same time, the issue of taking measures aimed at reducing the mortality rate [4,5,11,23,24,28,34,41], early diagnosis, prevention and treatment of the disease, the study of kidney complications, especially extra and intracranial complications after brain damage, which are considered to be problems of modern nephrology [1,3,8,9,32,33,37,38,43], remains an urgent problem [13,14,15,22,26,27,29,39,44]. Unfortunately, there is very little information in the available literature about the effect of different stages of brain damage on kidney morphology and function [2,16,17,18,19,30,31,40]. This situation calls for further research to determine the role of morphological changes in the kidneys as a result of brain injury.

Materials and methods: Three-month-old white rats with an average weight of 150 g were obtained for this study. All laboratory animals were housed in a vivarium in plastic cages lined with wood chips at room temperature with a 12-h light-dark cycle, in accordance with laboratory animal care standards. The animals of the experimental group were divided into 2 groups, i.e., the first group included animals without spinal cord injury (control, n=5), and the second group (experimental n=5) included animals with mild spinal cord injury. In the study, mild spinal cord injury was induced in white rats in a specially designed model using the "traffic accident" method.

During this experiment, all animals suffered mild to severe injuries. After the injury, the surviving animals were transferred to a special plastic cage and observed until recovery of the post-traumatic condition.

For histopathological comparison between the control and experimental groups, white rat kidneys were isolated on days 3, 14 and 21 after spinal cord injury, and samples were taken and preparations were made to determine the morphological changes occurring in the kidney tissues. All preparations prepared using standard histological techniques were stained with hematoxylin and eosin.

Research results: From the macroscopic point of view, the kidneys of the 3-month-old white rats of the experimental group are red-brown and bean-shaped located in the lumbar region, covered with a smooth and shiny capsule from the outside, no pathological changes visible from the macroscopic side were observed. Only a slight swelling was found.



1 - picture. Renal morphometry in white rats 3 months after moderate to severe traumatic brain injury.

Histological examination showed that a number of specific changes in the structure of nephrons of rat kidneys were revealed on the 3th, 14th and 21th days after moderate brain damage . In this case, the basal layer of the kidney has retained its structure in the nephrons and is enlarged due to the expansion of the renal corpuscle, the vascular ball of the kidney, and the Shumlyansky-Bowman capsule. was determined. This situation indicates that the filtration processes in it have decreased.

The same time, changes were observed in the proximal and distal egray tubules of nephrons under the influence of moderately severe brain injury.

The experimental group received moderate brain damage Karyolysis of proximal and distal convoluted tubule cells in 3-month-old white rat kidneys and medullary nephrons, the presence of erythrocytes in the tubules, the presence of focal hemorrhage zones between the tubules, dimming of the venous blood vessels due to the erythrocyte mass , interstitial swelling between the tissues presence was noted.

The morphological and morphometric parameters of the kidneys of rats three days after the moderately severe head injury were as follows: the absolute weight of the kidneys - from 714.12 mg to 1208.28 mg, the average weight - 920.78 ± 44.9 mg; kidney length - from 15.5 mm to 20.02 mm, average length - 17.79 ± 0.5 mm; width - from 6.24 mm to 10.9 mm, average width - 7.77 ± 0.5 mm; thickness - from 6.1 mm to 9.243 mm, average

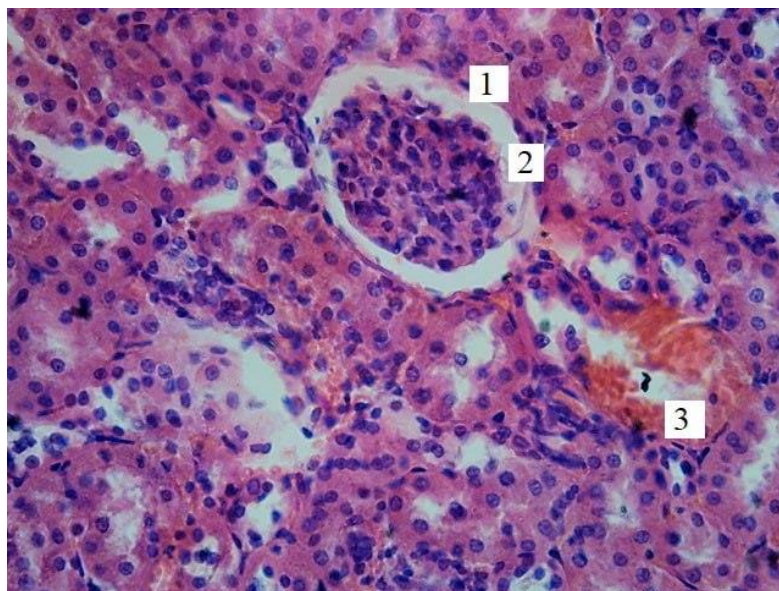
thickness - 7.74 ± 0.3 mm; it was noted that the volume of the kidney ranges from 383.89 mm^3 to 803.46 mm^3 , the average is $554.1 \pm 34.89 \text{ mm}^3$.

The area of kidney bodies is from $2179.3 \text{ }\mu\text{m}^2$ to $2400.2 \text{ }\mu\text{m}^2$, the average is $2294.19 \pm 21.1 \text{ }\mu\text{m}^2$; the area of the vascular ball - from $1776.4 \text{ }\mu\text{m}^2$ to $2094.6 \text{ }\mu\text{m}^2$, on average - $1915.28 \pm 24.0 \text{ }\mu\text{m}^2$; the area of the capsule cavity ranged from $315.41 \text{ }\mu\text{m}^2$ to $379.35 \text{ }\mu\text{m}^2$, the average value was equal to $351.53 \pm 5.5 \text{ }\mu\text{m}^2$.

The diameter of the proximal convoluted tubules is from $26.51 \text{ }\mu\text{m}$ to $39.27 \text{ }\mu\text{m}$, the average is $34.105 \pm 1.2 \text{ }\mu\text{m}$, the diameter of the tubular space is from $16.98 \text{ }\mu\text{m}$ to $19.75 \text{ }\mu\text{m}$, the average is $18.33 \pm 0.3 \text{ }\mu\text{m}$.

The diameter of the distal convoluted tubular tubules is from $26.54 \text{ }\mu\text{m}$ to $34.87 \text{ }\mu\text{m}$, the average is $31.96 \pm 0.8 \text{ }\mu\text{m}$, the diameter of the tubule cavity is from $15.56 \text{ }\mu\text{m}$ to $19.57 \text{ }\mu\text{m}$, the average is $17, 03 \pm 0.4 \text{ }\mu\text{m}$.

Fourteen days after moderately severe head injury, changes in the morphological and morphometric parameters of the kidneys of rats were as follows: the absolute weight of the kidneys - from 789.8 mg to 965.2 mg , the average weight - $865.58 \pm 16.6 \text{ mg}$; kidney length - from 16.08 to 21.33 mm , average length - $18.31 \pm 0.4 \text{ mm}$; width - from 6.24 mm to 8.55 mm , average - $7.42 \pm 0.2 \text{ mm}$; thickness - from 6.19 mm to 8.78 mm , average thickness - $7.44 \pm 0.2 \text{ mm}$; the volume of the kidney was from 421.03 mm^3 to 726.25 mm^3 , the average was $531.34 \pm 29.7 \text{ mm}^3$.

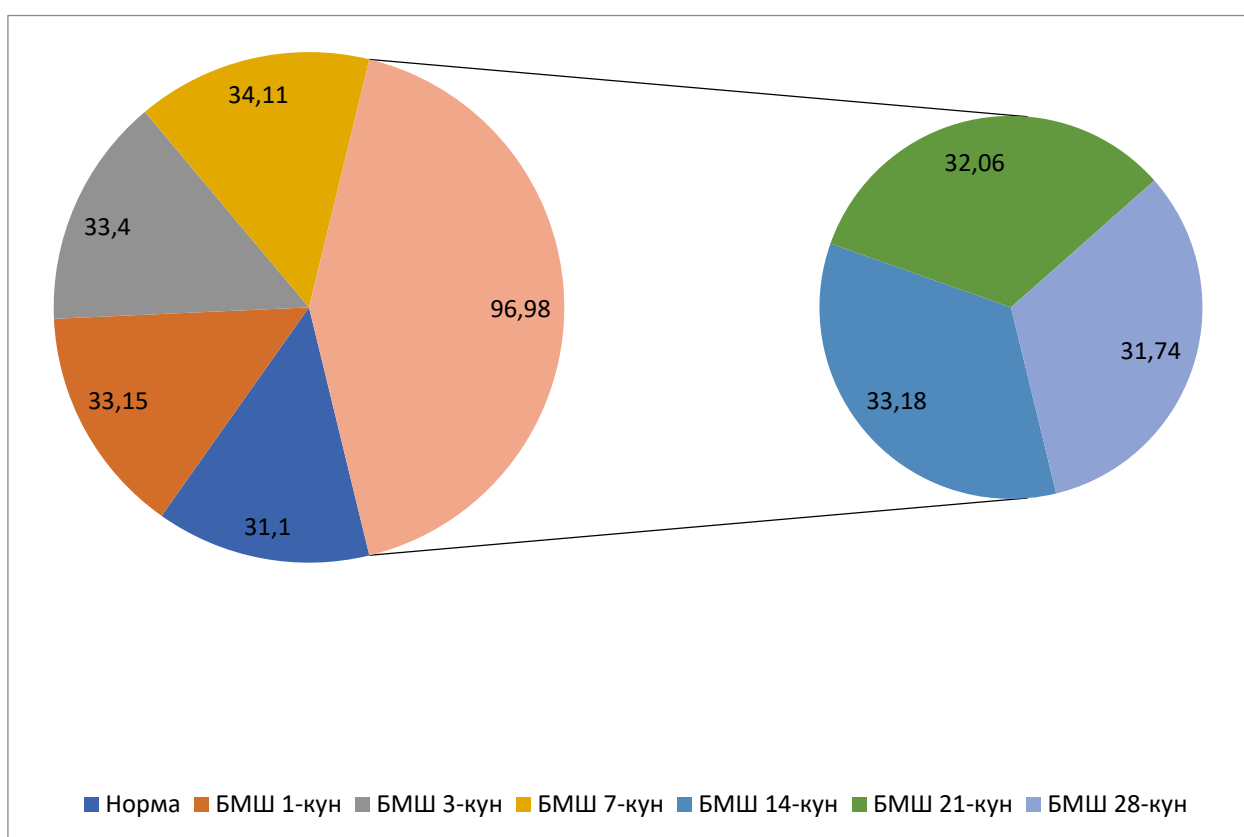


2 - picture. Cortical material of the kidneys of 3-month-old white rats with moderate brain injury of the study group (Stained with Hematoxylin-eosin. OK 10 x OB 40. 1-kidney ball, 2-Shumlyansky-Bowman capsule expansion, 3-focal hemorrhage zone)

The area of the kidney body is from 2018.2 μm^2 to 2316.83 μm^2 , the average is 2178.32 \pm 23.0 μm^2 ; the area of the vascular ball is from 1719 μm^2 to 1978 μm^2 , the average value is 1831.62 \pm 24.1 μm^2 ; it was determined that the area of the capsule cavity is 324.2 μm^2 to 345.2 μm^2 , the average is 333.76 \pm 1.6 μm^2 .

The diameter of the proximal convoluted tubules is from 29.4 μm to 39.6 μm , the average is 33.18 \pm 0.8 μm , the diameter of the tubular space is from 14.2 μm to 24.5 μm , the average is 18, 01 \pm 0.7 μm .

The diameter of the distal convoluted tubules is from 25.1 to 34.8 μm , the average is 30.3 \pm 0.8 μm , the diameter of the tubular cavity is from 13.1 to 18.9 μm , the average is 16 was 26 \pm 0.5 μm .



3 - picture. Comparative description of morphometric parameters of proximal and distal convoluted tubules in renal nephrons on the 1st, 3rd, 7th, 14th, 21st, 28th day after moderate brain injury.

Twenty-one days after a moderately severe head injury, the changes in the morphological and morphometric parameters of the kidneys of rats were as follows: the absolute weight of the kidneys - from 708.4mg to 965.3mg, the average weight - 852.85 \pm 26.2mg; kidney length - from 14.82 to 20.68 mm, average length - 17.43 \pm 0.6 mm; width - from 5.98 mm to 8.64 mm, average width - 7.312 \pm 0.3 mm; thickness - from 5.6 mm to 8.82 mm,

average thickness - 7.49 ± 0.3 mm; the volume of the kidney was from 334.65 mm³ to 824.2 mm³, the average was 510.39 ± 47.7 mm³.

The area of the renal corpuscle is from 1923.5 μm^2 to 2378.2 μm^2 , the average is 2129.23 ± 43.6 μm^2 ; the area of the vascular ball - from 1633.4 μm^2 to 1876.92 μm^2 , on average - 1768.06 ± 23.7 μm^2 ; the area of the capsule cavity ranged from 310 μm^2 to 379.54 μm^2 , the average was 327.201 ± 5.3 μm^2 .

The diameter of the proximal convoluted tubules is from 27.44 μm to 36.79 μm , the average is 32.06 ± 0.9 μm , the diameter of the cavity of the convoluted tubules is from 16.16 μm to 21 μm , the average is 17.52 ± 0.4 μm .

The diameter of the distal convoluted tubules is from 25.12 μm to 32.58 μm , on average - 29.2 ± 0.7 μm , the diameter of the cavity of the convoluted tubules is from 13.59 μm to 17.94 μm , on average - was 15.42 ± 0.4 μm .

Morphometric the results of the analysis showed that on the 14th day after a moderately severe brain injury, the area of the renal corpuscle, the area of the kidney ball, the area of the Shumlyansky-Bowman capsule, the diameter of the proximal and distal convoluted tubules, and the diameter of the tubule space in the kidney nephrons were found to have increased to a critical level. From the 21st day, the trend of decreasing histomorphometric indicators in nephron elements was noted. Histologically, after moderately severe brain injury, obvious changes in renal nephron elements were detected, which was confirmed by histomorphometric parameters.

Summary: Thus, as a result of macroscopic, histological and histomorphometric studies, moderate-severe brain damage of the experimental group received. A number of morphological changes were detected in the kidneys of 3-month-old white rats, especially. Maximal changes were obtained in the experimental group with moderately severe head injury. Significant changes were observed in the structure of kidney nephrons of white rats, and statistically significant differences were found in all studied indicators compared to the indicators of the control group of animals.

LITERATURE

1. Атаева, М. А. ПЛАНОВАЯ ИММУНИЗАЦИЯ-УДАР ПО ИНФЕКЦИЯМ. In *Материалы межвузовской научно-практической*

конференции «Актуальные вопросы медицины», инициированной ЮЖНО-КАЗАХСТАНСКОЙ МЕДИЦИНСКОЙ АКАДЕМИЕЙ И ШЫМКЕНТСКИМ МЕДИЦИНСКИМ ИНСТИТУТОМ МЕЖДУНАРОДНОГО КАЗАХСКО-ТУРЕЦКОГО УНИВЕРСИТЕТА ИМЕНИ ХА ЯСАУИ (р. 30).

2. Атаева, М. А., Баратова, М. С., & Кобилова, Г. А. (2019). Вирусные гепатиты, осложненные кардиомиопатиями. *Новый день в медицине*, 25(1), 91.

3. Атоева, М. А. (2020). Ограничительные меры во время эпидемий: исторический экскурс и проблемы настоящего времени. *Монография, «BUXORO NASHR»*.

4. Атоева, М. А. (2022). Эпидемический Процесс При Новой Коронавирусной Инфекции (Covid-19) И Его Профилактика. *Miasto Przyszłości*, 28, 57-59.

5. Атоева, М. А. (2023). Острые Респираторные Вирусные Инфекции В Период Пандемии. *Central Asian Journal of Medical and Natural Science*, 4(2), 184-189.

6. Атоева, М. А., & Жумамуратова, Б. С. (2021). Эпидемиологическая Характеристика Covid-19. *Central Asian Journal of Medical and Natural Science*, 51-54.

7. Атоева, М. А., & Хайитов, А. Х. (2022). Грипп в условиях пандемии коронавирусной инфекции. *Инфекция, иммунитет и фармакология*, 4, 53-57.

8. Атоева, М. А., Хайитов, А. Х., & Хакимов, Т. Б. (2023). БАКТЕРИАЛЬНЫЕ КОИНФЕКЦИИ В ПЕРИОД ПАНДЕМИИ COVID-19. *Finland International Scientific Journal of Education, Social Science & Humanities*, 11(5), 90-98.

9. Баратова, М. С., & Атаева, М. А. (2015). Оценка ранней дисфункции миокарда у больных с пороговой артериальной гипертензией и артериальной гипертензией I-степени. *Международный журнал прикладных и фундаментальных исследований*, (8-2), 232-233.

10. Баратова, М. С., & Атаева, М. А. (2018). РОЛЬ ОРВИ И ГРИППА В ФОРМИРОВАНИИ ОСЛОЖНЕНИЙ СЕРДЕЧНО-СОСУДИСТЫХ ЗАБОЛЕВАНИЙ. *Редакционная коллегия*, 35.

11. Баратова, М. С., Атаева, М. А., & Махмудова, М. Р. (2021). Диагностика коронавирусной инфекции при сердечно-сосудистой патологии и особенности течения карантина при Covid-19. *Биология и интегративная медицина*, (3 (50)), 47-66.

12. Баратова, М. С., Атаева, М. А., & Худойдодова, С. Г. (2017). Допплерграфия в диагностики нарушений функции миокарда левого желудочка после перенесенных инфекционных состояний. *Tibbiyotda yangi kun*, 4, 84-87.

13. Баратова, М. С., Атаева, М. А., Жалолова, В. З., & Рахматова, М. Р. (2016). Эффективность тиотриазолина при аритмиях. *Вестник Совета молодых учёных и специалистов Челябинской области*, 1(2 (13)), 4-6.

14. Баратова, М. С., Бакаев, И. К., Атаева, М. А., & Махмудова, М. Р. (2016). Чувствительность и специфичность показателей доплерографии в диагностике нарушений функции миокарда левого желудочка у больных с высоким нормальным артериальным давлением и мягкой артериальной гипертензией после перенесенных инфекционных состояний. *European research*, (6 (17)), 102-104.

15. Баратова, М. С., Бакаев, И. К., Атаева, М. А., & Махмудова, М. Р. 1Баратова Мехрибан Субиддиновна/Baratova Mehriban–кандидат медицинских наук, отделение кардиологии; 2Бакаев Илхом Курбанович/Bakaev Ikhom–главный врач, Бухарский областной кардиологический диспансер; 3Атаева Машхура Абборровна/Ataeva Mashkhura–кандидат медицинских наук. *EUROPEAN RESEARCH: INNOVATION IN SCIENCE, EDUCATION AND TECHNOLOGY*, 102.

16. Баратова, М. С., Кличев, А. Х., Атаева, М. А., & Собиров, С. Н. (2017). Применение тиотриазолина при суправентрикулярных и желудочковых экстрасистолах у пациентов с высоким нормальным артериальным давлением и мягкой артериальной гипертензией после перенесенных инфекционных состояний. *V съезд терапевтов Забайкальского края, 14-15 марта 2017 года, г. Чита [Электронный ресурс]: сборник научных трудов/Под общей ред. НВ Ларёвой; Читинская государственная медицинская академия.-Электрон. текстовые дан.-Чита: РИЦ ЧГМА, 2017.-1 электрон. опт. диск (CD-ROM)-Мин. систем. требования: IBM PS 100 МГц; 16 Мб RAM; Windows XP; AdobeReader Сборник содержит статьи и тезисы докладов работников Читинской государственной медицинс, 32.*

17. Баратова, М., Атаева, М., Мансурова, М., Кобилова, Г., & Махмудова, М. (2016). Допплерографии в диагностике нарушений функции миокарда лж у больных с высоким нормальным артериальным давлением и мягкой артериальной гипертензией после

перенесенных инфекционных состояний. *Журнал вестник врача*, 1(2), 13-15.

18. Баратова, М., Атаева, М., Мансурова, М., Сулейманов, С., Давлетова, С., Узакова, Н., & Суюнова, М. (2013). Дисплазия митрального клапана и её медикаментозное лечение. *Журнал проблемы биологии и медицины*, (1 (72)), 22-23.

19. Баратова, М., Атаева, М., Якубов, Ш., Мансурова, М., Саъдуллаева, Г., & Кобилова, Г. (2011). Оценка гемодинамических показателей у пациентов с синдромом дисплазии соединительной ткани сердца. *Журнал вестник врача*, 1(2), 55-56.

20. Г. Х . Хусейнова . Макроскопическая и микроскопическая характеристика почек белых беспородных крыс после тяжелой черепно-мозговой травмы. // *Вестник врача*. – 2021. № 1 (98). - С . 108 - 111.

21. Хусейнова Г.Х. , Тешаев Ш. Ж. Поведенческие реакции белых нескучных крыс за счет черепно -мозговой травмы, вызванной дорожно-транспортным происшествием. // *Проблемы биологии и медицины*. - 2021. № 2 (127). - С . 219 -220.

22. Хусейнова Г.Х. _ Влияние лекарственных препаратов на поведенческие реакции животных посттравматического периода. // *Новый день в медицине*. – 2021. № 2 (34/1). - С . 88 -91.

23. Хусейнова Г.Х. _ Оценка почек при черепно-мозговой травме. *Журнал природных средств правовой защиты*. // Том. 22, № 1(2), (2021).

24. Хусейнова Г.Х. _ Результаты морфологических особенностей строения почек после тяжелой черепно -мозговой травмы. // *Американский журнал медицины и медицинских наук* 2021. № 11 (4): 293-296.

25. Хусейнова Г.Х., Тешаев Ш.Ж Морфологические особенности почек в условиях экспериментальной черепно-мозговой патологии. // *Проблемы биологии и медицины*. - 2021. № 1 (125). - С. 151 -153.

26. Хусейнова Г.Х., Тешаев Ш.Ж. Морфологические особенности почек в условиях экспериментальной черепно-мозговой тревоги. // *Проблемы биологии и медицины*. - 2021. № 1 (125). - С. 151 - 153.

27. Хусейнова Г.Х., Тешаев Ш.Ж. Сравнительная характеристика морфометрических параметров почек при различных

фазах черепно-мозговой инфекции. // Новый день в медицине. – 2020. № 2/1(30/1). - С. 101 -103.

28. Хусейнова Г.Х., Файзиев Х.Б. Макроскопическая топография почек 3 месячных крыс после черепно-мозговой тяги. // Проблемы биологии и медицины 2021. № 2 (127). - С. 221 -223.

29. Ataeva, M. A., & Baratova, M. (2021). Diagnosis of heart rhythm disorders at early stages of left ventricular remodeling. *Central Asian Journal of Medical and Natural Science*, 2(3), 107-112.

30. Atayeva, M. A. (2020). Cardiomyopathy as a Manifestation of Complications of Chronic Viral Hepatitis. *American Journal of Medicine and Medical Sciences*, 10(4), 258-261.

31. Atoeva, M. (2023). EPIDEMIOLOGICAL FEATURES OF INFLUENZA AND SARS DURING THE CORONAVIRUS INFECTION PANDEMIC. *JOURNAL OF HEALTHCARE AND LIFE-SCIENCE RESEARCH*, 2(5), 71-77.

32. ATOEVA, M. A., BARATOVA, M. S., & Jumamuratova, B. S. (2021). PREVALENCE OF VIRAL HEPATITIS" B" AND" C" AMONG MEDICAL WORKERS. *Journal of natural remedies*, 22(1 (2)), 54-59.

33. Atoeva, M. A., Baratova, M. S., Kobilova, G. A., & Hakimov, T. B. (2022). Predictive Models For Efficient Commerce Management In A Virtual Environment. *Journal of Positive School Psychology*, 6(7), 5190-5198.

34. ATOEVA, M., & Baratova, M. S. (2021). JUMAMURATOVA BS PREVALENCE OF VIRAL HEPATITIS" B" AND" C" AMONG MEDICAL WORKERS. *Journal of natural remedies*, 22(1), 2.

35. Atoeva, M., & Khayitov, A. (2022). Peculiarities of influenza virus circulation during the coronavirus pandemic. *Scientific Collection «InterConf»*, (127), 162-163.

36. Atoyeva, M. A., & Jumamuratova, B. S. (2021). Psychoemotional factors related to COVID-19 quarantine. *апрель-июнь*, 98.

37. Baratova, M. S., Ataeva, M. A., & Berdiev, U. A. (2022). Sars and Influenza in the Formation of Complications Heart Rhythmthe. *AMALIY VA TIBBIYOT FANLARI ILMIY JURNALI*, 1(2), 15-20.

38. Baratova, M. S., Ataeva, M. A., Yuldasheva, S. T., & Vohidov, U. G. (2020). Periodontal diseases in military age persons and arterial hypertension. *Asian Journal of Multidimensional Research (AJMR)*, 9(4), 111-113.

39. BARATOVA, M. S., ATAYEVA, M. A., & HALIMOVA, D. S. (2020). Modern Ultrasound Methods for Assessing Indicators of The Latent

Diastolic Function of The Left Ventricle. *International Journal of Pharmaceutical Research* (09752366), 12(3).

40. Gulshan Khuseynovna Khuseynova. (2021). EVALUATION OF MORPHOLOGICAL CHANGES OF THE KIDNEYS IN CEREBRAL TRAUMA . *Journal of Natural Remedies*, 22(1(2), 87-94.

41. Kh, G. (2021). Khuseynova. Macroscopic and microscopic characteristics of kidneys of white unbored rats after severe cranial injury. *The Doctor's Newsletter*, (1), 98.

42. Kh, K. G., & Sh, T. (2020). Zh.// "Comparative characteristics of the morphometric parameters of the kidneys in different phases of traumatic brain injury.". *Tibbietda yangi kun-2020*, 2(1), 30.

43. Kh, K. G., & Sh, T. (2021). Zh. Morphological features of the kidneys in conditions of experimental traumatic brain injury. *Problems of Biology and Medicine*, (1), 125.

44. Khuseynova Gulshan Khuseynovna. (2022). ASSESSMENT OF MORPHOLOGICAL CHANGES IN THE KIDNEYS IN EASY DEGREE OF ACUTE PERIOD OF CRANIO-BRAIN INJURY. "ONLINE - CONFERENCES" PLATFORM, 307-308.

УДК: 611-018.61:616.831.001(756):616-092.2

ЎРТАЧА ОҒИР ДАРАЖАДА БОШ МИЯ ШИКАСТЛАНИШИНИНГ ЎТКИР ОСТИ ДАВРИДА 7- ВА 14 -КУНИ БУЙРАКЛАРНИНГ МОРФОЛОГИК ХУСУСИЯТЛАРИ

Хусейнова Гулшан Хусейновна.

<https://orcid.org/my-orcid?orcid=0000-0001-8773-9999>

*Бухоро давлат тиббиёт институти анатомия,
клиник анатомия (ОХТА) кафедраси*

Аннотация: Ушбу мақолада ўртача оғир даражадаги бош миянинг шикастланиши оқибатида 3 ойлик каламушлар буйракларининг морфологик хусусиятларини баҳолаш ва ўрганиш мумкин бўлган илмий тадқиқотлар натижалари ҳақида маълумотлар келтирилган. Каламуш буйракларини морфологик таҳлили бош мия шикастланишдан кейинги 7-, 14- кунларда ўтказилган.

Калит сўзлар: бош мия шикастланиши, буйраклар, нефрон, биоптат, Шумлянский-Боумен капсуласи, томирли коптокча.