

**ФУНДАМЕНТАЛ ВА
КЛИНИК ТИББИЁТ
АХБОРОТНОМАСИ**

**BULLETIN OF FUNDAMENTAL
AND CLINIC MEDICINE**

2026, №2 (22)

МИНИСТЕРСТВО ЗДРАВООХРАНЕНИЯ
РЕСПУБЛИКИ УЗБЕКИСТАН

**BULLETIN OF FUNDAMENTAL
AND CLINIC MEDICINE**
**ФУНДАМЕНТАЛ ВА КЛИНИК
ТИББИЁТ АХБОРОТНОМАСИ**
**ВЕСТНИК ФУНДАМЕНТАЛЬНОЙ И
КЛИНИЧЕСКОЙ МЕДИЦИНЫ**

Научный журнал по фундаментальным и клиническим
проблемам медицины
основан в 2022 году

Бухарским государственным медицинским институтом
имени Абу Али ибн Сино
выходит один раз в 2 месяца

Главный редактор – Ш.Ж. ТЕШАЕВ

Редакционная коллегия:

*С.С. Давлатов (зам. главного редактора),
Р.Р. Баймурадов (ответственный секретарь),
М.М. Амонов, Г.Ж. Жарилкасинова,
А.Ш. Иноятов, Д.А. Хасанова, Е.А. Харибова,
Ш.Т. Уроков, Б.З. Хамдамов, Ф.К. Халлоқов*

*Учредитель Бухарский государственный
медицинский институт имени Абу Али ибн Сино*

2026, № 2 (22)

Адрес редакции:

Республика Узбекистан, 200100, г.
Бухара, ул. Гиждуванская, 23.

Телефон (99865) 223-00-50

Факс (99866) 223-00-50

Сайт <https://bsmi.uz/journals/fundamental-ya-klinik-tibbiyot-ahborotnomasi/>

e-mail baymuradovravshan@gmail.com

О журнале

Журнал зарегистрирован
в Управлении печати и информации
Бухарской области
№ 1640 от 28 мая 2022 года.

Журнал внесен в список
утвержденный приказом № 370/б
от 8 мая 2025 года реестром ВАК
в раздел медицинских наук.

Отпечатано в типографии ООО
“Шарк-Бухоро”. г. Бухара,
ул. Ўзбекистон Мустақиллиги, 70/2.

Редакционный совет:

Абдурахманов Д.Ш.	(Самарканд)
Абдурахманов М.М.	(Бухара)
Ахмедов Р.М.	(Бухара)
Баландина И.А.	(Россия)
Бахронов Ж.Ж.	(Бухара)
Бернс С.А.	(Россия)
Газиев К.У.	(Бухара)
Деев Р.В.	(Россия)
Дустова Н.К.	(Бухара)
Зокирова Н.Б.	(Ташкент)
Казакова Н.Н.	(Бухара)
Калашникова С.А.	(Россия)
Каримова Н.Н.	(Бухара)
Курбонов С.С.	(Таджикистан)
Маматов С.М.	(Кыргызстан)
Мамедов У.С.	(Бухара)
Мирзоева М.Р.	(Бухара)
Миршарапов У.М.	(Ташкент)
Набиева У.П.	(Ташкент)
Нуралиев Н.А.	(Хорезм)
Наврұзов Р.Р.	(Бухара)
Нарзиева Д.Ф.	(Бухара)
Орипов Ф.С.	(Самарканд)
Орипова Ф.Ш.	(Бухара)
Одилова Г.Р.	(Бухара)
Очилов К.Р.	(Бухара)
Раупов Ф.С.	(Бухара)
Рахмонов К.Э.	(Самарканд)
Рахметов Н.Р.	(Казахстан)
Рахматова С.Н.	(Бухара)
Султонова Л.Дж.	(Бухара)
Сайдуллаев З.Я.	(Самарканд)
Удочкина Л.А.	(Россия)
Файзиев Х.Б.	(Бухара)
Хамдамова М.Т.	(Бухара)
Хамдамов И.Б.	(Бухара)
Ходжаева Д.Т.	(Бухара)
Худойбердиев Д.К.	(Бухара)
Халлоков Ф.К.	(Бухара)
Шодиева М.С.	(Бухара)
Эшонов О.Ш.	(Бухара)

RESULTS OF MORPHOLOGICAL AND MORPHOMETRIC CHANGES IN THE RECTUM AS A RESULT OF CHEMOTHERAPY IN EXPERIMENTAL BREAST CANCER

Ashurova Sh.U., Kharibova E.A.

Bukhara State Medical Institute named after Abu Ali ibn Sino, Bukhara, Uzbekistan

Resume. In a study of the small intestinal mucosa of mice, the height of the intestinal villi increased by 35% when following a high-calorie diet containing 10% fat (417 μm in the control group and 563 μm in the experimental group). A decrease in the number of absorptive areas per mm^2 in the rectum was observed in rats maintained on a diet with 32% fat content. Experimental models showed an enlargement of the intestinal cavity, which leads to the development of obesity. Standard nutrition over a period of 5 weeks (a diet with 14% fat content) showed signs of inflammation developing in the epithelium of the rectal mucosa.

Keywords: breast cancer, rectum, morphology, chemotherapy.

ТАЖРИБАВИЙ СУТ БЕЗИ РАКИДА КИМЁТЕРАПИЯ ТАЪСИРИДА ТЎҒРИ ИЧАКДАГИ МОРФОЛОГИК ВА МОРФОМЕТРИК ЎЗГАРИШЛАР НАТИЖАЛАРИ

Ашурова Ш.Ў., Харибова Е.А.

Абу Али ибн Сино номидаги Бухоро давлат тиббиёт институти, Бухоро ш., Ўзбекистон

Резюме. Каламушларнинг ингичка ичак шиллиқ қавати устида олиб борилган тадқиқотда, 10% ёғли юқори калорияли диета қўлланилган гуруҳда ингичка ичак сўргичлари баландлиги 35% га ошгани кузатилди (назорат гуруҳида 417 мкм, тажриба гуруҳида 563 мкм). Калориялиги юқори (32% ёғли) диета билан боқилган каламушларда тўғри ичакда ҳар мм^2 га тўғри келувчи сўриш майдончаларининг камайгани кузатилди, бу эса ичак бўшлигининг кенгайишига ва семириш ривожланишига олиб келди. Стандарт овқатланиш (5 ҳафта давомида 14% ёғли диета) эса тўғри ичак шиллиқ қавати эпителийсиди яллиғланиш белгилари ривожланаётганини кўрсатди.

Калит сўзлар: сут беши раки, тўғри ичак, морфология, кимётерапия.

РЕЗУЛЬТАТЫ МОРФОЛОГИЧЕСКИХ И МОРФОМЕТРИЧЕСКИХ ИЗМЕНЕНИЙ ПРЯМОЙ КИШКИ В РЕЗУЛЬТАТЕ ХИМИОТЕРАПИИ ПРИ ЭКСПЕРИМЕНТАЛЬНОМ РАКЕ МОЛОЧНОЙ ЖЕЛЕЗЫ

Ашурова Ш.У., Харибова Е.А.

Бухарский государственный медицинский институт имени Абу Али ибн Сино, г. Бухара, Узбекистан

Резюме. В исследовании слизистой оболочки тонкого кишечника мышей высота ворсинок тонкого кишечника увеличивалась на 35% при соблюдении высококалорийной диеты с использованием 10% жира (417 мкм в контрольной группе и 563 мкм в экспериментальной группе). Уменьшение количества всасываний на мм^2 прямой кишки при содержании крыс на диете с содержанием жиров 32% экспериментальные модели показали увеличение кишечной полости, что приводит к развитию ожирения, и стандартное питание в течение 5 недель (диета с содержанием жиров 14%) показало признаки развития воспаления в эпителии слизистой оболочки прямой кишки.

Ключевые слова: рак молочной железы, прямой кишке, морфология, химиотерапия.

e-mail: xaribova.elena@bsmi.uz

Relevance of the study. Cancer is a multifactorial disease in which many factors lead to a single outcome. Having uncovered the mysteries of poor-quality tumor growth, scientists have studied and characterized many characteristics of cancer cells, but the underlying cause of a healthy cell's transformation into a poor-quality cell remains unclear. The cause of tumor development is one of the most pressing and controversial issues in modern medical science. Environmental factors, as well as internal dysfunctions, also create the conditions for tumor growth. Environmental factors determine the development of primary and secondary factors among a large number of factors. Science already knows that 80 to 90 percent of human cancer cases are caused by environmental and lifestyle factors.

Identifying, reducing, and eliminating these factors reduces the risk of developing tumors. Cancer has been shown to be caused by exposure to chemicals, ionizing radiation, ultraviolet radiation, viruses, mechan-

ical damage, and many other factors. All chemical factors are called carcinogens. The likelihood of developing cancer is determined not only by the duration and intensity of exposure to a carcinogen but also by the body's condition. Carcinogens can also be found in food and water, as well as in the air in our homes or industrial buildings.

Carcinogens, which can damage healthy cells, can be found in household chemicals and perfumes. They can be liquid or gaseous, and can even affect us through fields that are completely invisible and detectable only by specialized equipment. Surprisingly, even sunlight can have a carcinogenic effect. It is impossible to completely eliminate contact with carcinogens in our daily lives, but we can minimize their harmful effects. To do this, we must understand which factors are dangerous and how to prevent their exposure. The causes of malignant tumors have long been known when we think of chemicals. Even the study of the influence of certain chemicals on the formation of malignant tumors dates back over 200 years. It is not yet fully understood how carcinogens cause normal cells to acquire characteristics characteristic of malignant growth. In recent years, researchers have come closer to solving this problem by uncovering some mechanisms of chemical carcinogenesis. Chemical carcinogens are organic and inorganic compounds of various structures. They are present in the environment and can be toxic substances produced by the body or cellular metabolites.

Study objective: to study morphological changes in the rectum caused by chemotherapy for breast cancer and the effectiveness of bicorrection with pomegranate seed oil, as well as to identify morphological and morphometric features and correlate them.

Study materials and methods: Experiments were conducted on 200 female white mongrel rats born in a vivarium. Rats were 6 months old. Ethical requirements for the use of animals in experiments were observed. Before the experiments, all sexually mature rats were quarantined for a week, and after somatic or infectious diseases were excluded, they were transferred to the vivarium under the same conditions as usual. During the experiment, the behavior and physiological state of the animals in the normative and experimental groups were monitored. The rats were divided into 5 groups (n=200): group 1 control group (n=40); groups 2-5 (n=160) experimental animals from 6 months of age to detect mammary cancer in the experimental groups, rats were induced to develop mammary cancer using the carcinogenic agent 7,12-dimethylbenzanthracene. This gave a result of 68.9%, which means that 160 female rats were induced to develop mammary cancer in 110 rats by administering the carcinogen 7,12-dimethylbenzanthracene subcutaneously into the mammary gland area at a dose of 0.1 mg. After that, we divided 111 outbred white rats with mammary cancer into 4 more groups. Group 2 (n=28) in the experiment, rats with cancer were administered intravenous paclitaxel at a dose of 0.2 mg/kg and 0.7 ml of distilled water were administered intragastrically through a metal tube in the stomach for 21 days; group 3 (n=28) rats with cancer were administered intravenous paclitaxel at a dose of 0.2 mg/kg. Thymalin was administered as an intramuscular injection at a dose of 0.01 mg/day for 7 days; rats, experimental animals of group 4 (n=28) with cancer, were administered intravenously paclitaxel at a dose of 0.2 mg/kg and intragastric administration of 0.7 ml of pomegranate seed oil through a metal tube in the stomach for 21 days; Group 5 (n=27) rats with cancer were administered paclitaxel intravenously at a dose of 0.2 mg/kg and pomegranate seed oil intragastrically via a metal gastric tube for 21 days as an intramuscular injection of 0.7 ml, as well as Thymalin at a dose of 0.01 mg per day for 7 days.

Research results and discussion. In an experiment with breast cancer, acute inflammatory changes developed under chemotherapy, and remodeling of the colonic mucosa architecture was observed. The number of goblet cells decreased, and the cellular composition was represented mainly by lymphocytes, plasma cells, macrophages, and isolated neutrophils. In the control group, a sharp increase in the number of mast cells was recorded compared to the experimental animals, most of which were in a degranulated form. The data obtained suggest damage to the histological structures of the colon of experimental animals under the influence of chemotherapy and are consistent with current literature on the inflammatory effects of chemotherapy on the intestine. The development of chronic inflammation in the rat colon occurred alongside the development of inflammatory and traumatic morphological changes in the colon wall (Fig. 1).

The structure of the intestine in mammals and humans, however, is very similar. The large intestine consists of the cecum, colon, sigmoid colon, and rectum. The intestinal wall structure (regardless of the section) is typically divided into the mucosal, submucosa, muscularis, and serosal layers. The intestinal mucosa consists of a single-layered columnar epithelium of the intestinal type. In mammals, the length of the colon varies depending on the species. The mucosa of the rectum has a specific topography, forming crescent-shaped folds and crypts. The morphometric characteristics of these structures in animals depend on the species, that is, on the structure and type of food. Epithelial cells are divided into sucking, goblet, endocrine, Panethial, and stem cells. Sucking epithelial cells consist of two cell types: framed and unframed. The main

function of these cells is to ensure absorption. The degree of differentiation of goblet cells varies depending on their location. The cells of the endocrine crypt epithelium vary in composition and secretory pattern. Paneth cells are located in the crypts, and some literature suggests that Paneth cells are absent from the colonic mucosa. Normally, the rat rectal mucosa consists of folds that increase the intestinal surface area. The colon also contains numerous unbranched crypts, the lower portions of which contain a small group of stem cells. The colonic crypt depth in 6-month-old rats was $-187 \pm 73 \mu\text{m}$. The intercellular spaces are filled with porous fibrous connective tissue. The crypts contain goblet cells, which produce large quantities of mucus, protect the mucosal epithelial surface, and ensure easy, slippery stool movement. In the lamina propria, we see a large accumulation of lymphoid tissue. In our experiment, the structure of the rectal epithelium of rats transitioned caudally from columnar epithelium to stratified cuboidal epithelium, and then abruptly to stratified squamous nonkeratinizing epithelium, which gradually gave way to skin-type (keratinizing) epithelium. Crypts in the rectal mucosa are deeper than in the colon, but they are located less frequently. Crypts are absent in the lower part of the rectum. The epithelium contains a large number of intraepithelial lymphocytes. The lamina propria contains numerous lymphoid nodes, sometimes alternating with larger nodes. The muscularis mucosa consists of an inner circular and an outer longitudinal layer of smooth muscle cells. The submucosa, on the other hand, consists of irregular, porous fibrous connective tissue (Fig. 2).

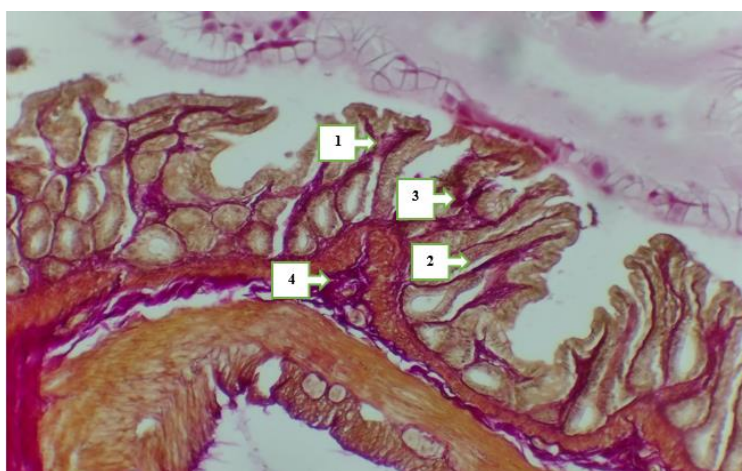


Fig. 2. Colonic mucosa of experimental group rats. Vanguison staining. Ok 10 x 40 ob x 100. 1 - goblet cells, 2 - columnar cells, 3 - blood microclots, 4 - signs of inflammation.

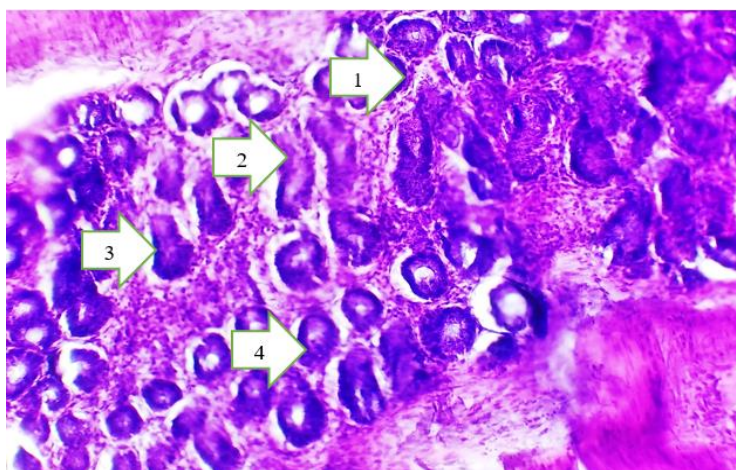


Fig. 2. Colonic mucosa of experimental rats. Hematoxylin and eosin staining. 10 x 40 magnification. 1 - crypts, 2 - deep crypts, 3 - goblet cells, 4 - columnar cells.

The muscular layer consisted of two layers: an inner circular layer and an outer longitudinal layer, which formed three longitudinally directed bands. Because they are shorter than the colon, this resembles an "accordion" appearance. The intestine serves as a barrier between the internal and external environments of the body, while the colon absorbs water from chyme, forms stool, and excretes various substances. The walls of the digestive tract, including the wall of the colon, also consist of the inner mucosa (tunica mucosa), submucosa (submucosa), muscularis (tunica muscularis), and outer serous layer (tunica serosa) or adventitia (tunica adventitia). The mucosa, in turn, consists of the epithelium, lamina propria, and muscularis mucosa. The

epithelium of the rectum is covered by single-layered columnar cells, which contain the main populations of epithelial cells and epithelial intercellular lymphocytes. Colonocytes in the rectum make up the bulk of the epithelial layer and ensure the absorption and transport of nutrients, water, and electrolytes. Secretory epithelial cells consist of goblet cells, Paneth cells, and enteroendocrine cells. Goblet cells (exocrinocytes) of the rectum produce neutral and acidic glycoproteins (mucins), which are the main components of the intestinal mucosa. Their abundance in the intestinal mucosa increases from the duodenum to the colon, and they constitute approximately 50% of all colonic epithelial cells. Goblet cells form a sticky-elastic mucous substance on the mucosal surface, lining the mucosa. This mucous substance, in turn, facilitates the movement of chyme, protecting the epithelial layer from mechanical damage. Furthermore, the prostate gland participates in digestion, forming the basis of a biofilm for microflora. In the small intestine, the mucous substance is single-layered, while in the large intestine, it is bilayered (Fig. 3).

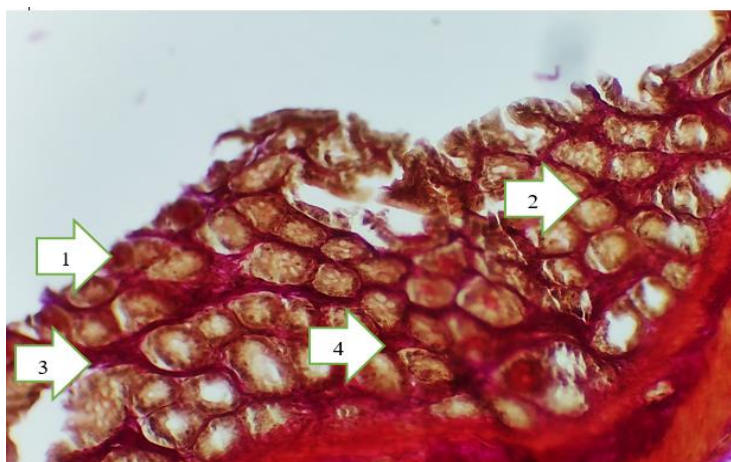


Fig. 3. Rectal mucosa from an experimental group of rats. Vanguison staining. OC 10 x 40 magnification. 1 - goblet cells, 2 - columnar cells, 3 - glandular outflow tract, 4 - intercellular substance.

Paneth cells, or exocrine cells, are cells with a granular apical portion containing acidophilic granules. They secrete lysozyme, which may have antibacterial and anti-inflammatory effects. It is believed that Paneth cells in humans exist only in the small intestine, but modern data show that they are also found in the rectum.

Conclusions. In the experiment, chemotherapy for breast cancer negatively affected all parameters of rectal structures. When treated with pomegranate seed oil, positive changes in organometric and morphological parameters were observed in the experimental groups. Chemotherapy for breast cancer mainly caused a decrease in rectal length, crypt depth, the number of goblet and columnar cells, but also an increase in the number of cellular elements of rectal tissue (lymphocytes, neutrophils, macrophages and mast cells).

References:

1. Алиев К. А. и др. Анализ эффективности режимов неoadьювантной химиотерапии у пациентов с местнораспространенным HER2/неу-негативным раком молочной железы: нерандомизированное сравнительное исследование //Кубанский научный медицинский вестник. – 2025. – Т. 32. – №. 2. – С. 29-40.
2. Бахронов Ж. Ж. Эффективность коррекции маслом косточек граната химиотерапии при раке молочной железы //Solution of social problems in management and economy. – 2024. – Т. 3. – №. 3. – С. 11-13.
3. Ена М. С., и др. Влияние производного пиролана на слизистую оболочку толстой кишки крыс в сравнении с 5-фторурацилом //Український журнал медицини, біології та спорту. – 2016. – №. 1. – С. 139-143.
4. Ермакова А. В. и др. Морфологические и анатомические особенности лабораторных белых крыс //Материалы Всероссийской научно-практической конференции «Неделя студенческой науки». – 2023. – С. 103-105.

For citation: Ashurova Sh.U., Kharibova E.A. Results of morphological and morphometric changes in the rectum as a result of chemotherapy in experimental breast cancer // Bulletin of Fundamental and Clinic Medicine. – 2026. – № 2(22). – P. 523–526. doi: <https://doi.org/10.5281/zenodo.18720747>